

Modified Hemostatic Technique Using Microfibrillar Collagen Hemostat in Endoscopic Endonasal Transsphenoidal Surgery: Technical Note

Yasunori FUJIMOTO,¹ Taisuke KOBAYASHI,² Masahiro KOMORI,² Pedro MARIANI,³ Edson BOR-SENG-SHU,⁴ Manoel Jacobsen TEIXEIRA,⁴ Akatsuki WAKAYAMA,¹ and Toshiki YOSHIMINE⁵

¹Department of Neurosurgery, Osaka Neurological Institute, Toyonaka, Osaka;

²Department of Otorhinolaryngology, Kochi Medical School, Kochi University, Nankoku, Kochi;

³Department of Neurosurgery, Hospital de Transplantes Euryclides de Jesus Zerbini, São Paulo, Brazil;

⁴Division of Neurological Surgery, Hospital das Clínicas, University of São Paulo School of Medicine, São Paulo, Brazil;

⁵Department of Neurosurgery, Osaka University Graduate School of Medicine, Osaka, Osaka

Abstract

Microfibrillar collagen hemostat (MCH) is accepted as an effective topical hemostatic agent during endoscopic endonasal transsphenoidal surgery (EETS), particularly to achieve venous hemostasis; however, handling MCH may be troublesome because of its adherence to gloves and instruments. We describe here a method of “injection” of MCH suspension using a syringe applicator. This technique allows a rapid and precise delivery of MCH to the bleeding points and thereby results in effective hemostasis; in addition, it is easy to prepare and it is also inexpensive.

Key words: endoscopic endonasal transsphenoidal surgery, microfibrillar collagen hemostat, topical hemostat

Introduction

Various topical hemostatic agents have been developed for neurosurgery, because electrocoagulation is not effective in many situations to achieve hemostasis. In endoscopic endonasal transsphenoidal surgery (EETS), it may be sometimes difficult to precisely deliver a topical hemostat to the bleeding points, because handling commonly employed hemostats with forceps may be troublesome because of the narrow and deep surgical field. We describe here a simple method of “injection” of microfibrillar collagen hemostat (MCH) in a suspended form. Hemostatic technique using an MCH suspension has been previously described in cardiovascular and spine surgeries, although there are no reports referring specifically to its application in EETS.

Materials and Methods

From January 2012 to December 2013, we performed

EETS for pituitary lesions using binostril approach with two-surgeon technique in 10 consecutive patients. The injection method of MCH suspension was performed for hemostasis in all cases when we encountered bleeding from the dura mater of the sella floor, the cavernous sinus, the bony margins of exposure, and the tumor bed; bleeding could not be controlled by the standard hemostatic techniques using oxygenized regenerated cellulose (Surgicel®; Ethicon Inc., Johnson & Johnson Company, Somerville, New Jersey, USA), gelatin sponge (Gelfoam®; Pharmacia and Upjohn Company, Kalamazoo, Michigan, USA), bone wax, or electrocautery. We also applied the MCH suspension in place of swollen Surgicel® or Gelform® that interfered continued procedures. We received informed consent from all patients before surgery.

Hemostatic technique using MCH suspension

A pasty mixture was prepared by aseptically mixing 1 g of Avitene® flour MCH (Davol Inc, Woburn, Massachusetts, USA) with 9 mL of saline, filled into a 10-mL syringe, which was connected

Received January 26, 2014; Accepted April 14, 2014

with another empty syringe using a three-way stopcock, and agitated by a pumping motion to turn the mixture into a suspension (Fig. 1A). The hemostat suspension was subsequently injected into the bleeding points through the nostril using a cannula (2 mm diameter) (Figs. 1B and 2A, B, E). This optimal volume of saline for making the mixture had been determined according to a viscosity that was enough for the suspension not

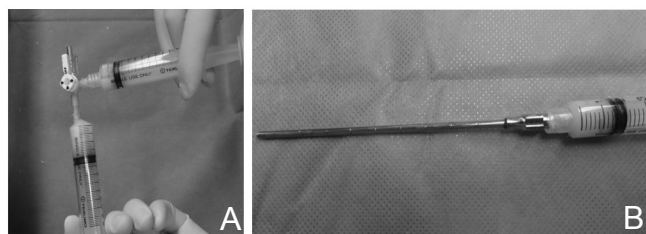


Fig. 1 Preparation of microfibrillar collagen hemostat (Avitene®) suspension. A: A pasty mixture prepared by mixing Avitene® flour with 9 mL of saline filled into a 10-mL syringe connected with another empty syringe using a three-way stopcock. The paste is agitated by pumping motion to turn it into a suspension. B: Syringe applicator containing Avitene® suspension for the injection method.

only to be injected smoothly through the cannula, but also to remain where it was placed. A surgical patty was immediately layered over the hemostat and gently compressed using a suction tube through which excess moisture was absorbed (Fig. 2C). Reapplication of the hemostat was possible in cases of persistent bleeding. Once hemostasis was achieved (Fig. 2D), excess hemostat was removed by irrigation with saline flow and careful suction.

Results

The patients' characteristics are shown in Table 1. There were 6 male and 4 female patients, ranging in age from 12 years and 71 years (mean, 48 years). The pathology of the patients included 8 patients with non-functioning pituitary adenomas, one with Rathke's cleft cyst and one with germinoma. Bleeding from the cavernous sinus during resection of the tumor was encountered in two cases (Case 1 and Case 7). The follow-up period was between 2 months and 24 months (mean: 10 months). The time taken to prepare MCH suspension was approximately 3 min. The quantity of one injection was approximately 1 mL for the bleeding from the dura mater or bony margins and 2 mL for that from the cavernous

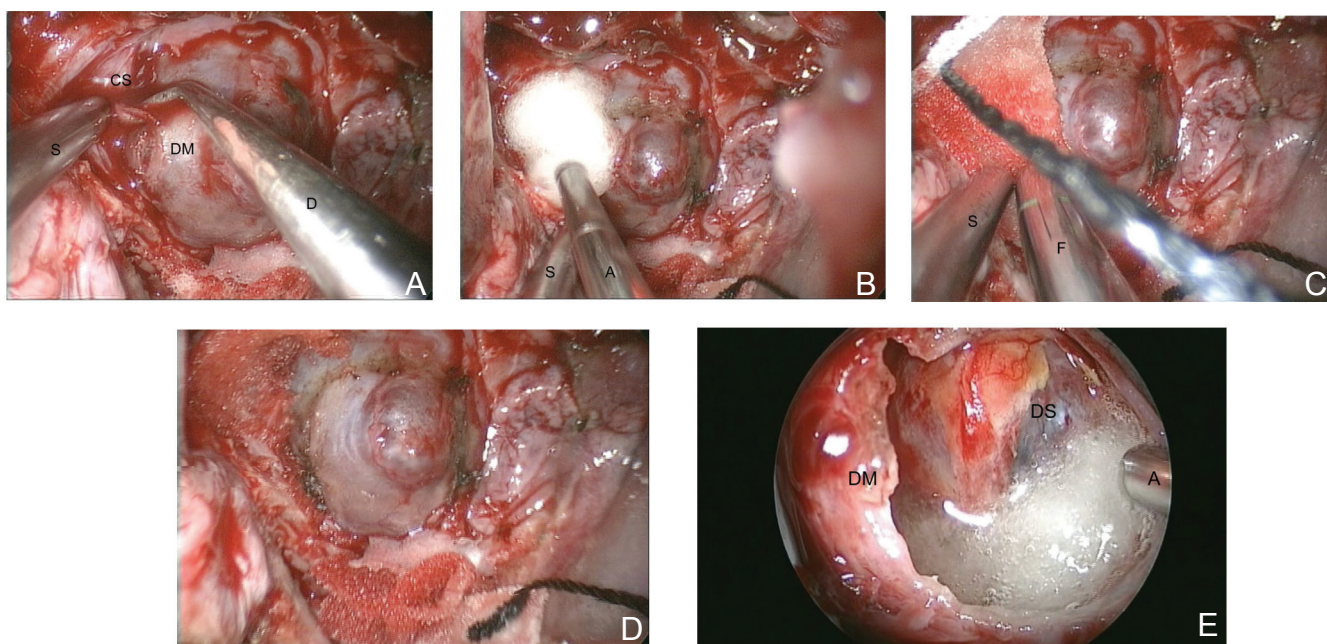


Fig. 2 Procedures of injection of Avitene® suspension to achieve hemostasis (A–D: Case 1, E: Case 2). A: Venous bleeding from the dura mater covering cavernous sinus during exposure of the right lateral portion of the sella. B: Injection of Avitene® suspension to the bleeding point. C: Application of a surgical patty over the Avitene® suspension, followed by compression using a suction tube. D: Complete hemostasis is achieved after the application of compression for a few minutes. E: Injection of the Avitene® suspension into the tumor bed to control venous oozing after tumor removal. A: applicator tip, CS: cavernous sinus, D: dissector, DM: dura mater, DS: diaphragm sellae, F: forceps, S: suction tube.

Table 1 Patient characteristics

Case No	Age (yrs)	Sex	Pathology	CS invasion	Surgery	Bleeding point	Total volume of the injected hemostat (mL)	Perioperative complications	Follow-up (months)
1	62	F	NFA	+	PR	DM, BM, CS	6	None	24
2	50	M	NFA	-	TR	DM	2	None	21
3	29	F	NFA	-	TR	BM	3	None	21
4	60	M	RCC	-	Cyst decompression and biopsy	DM	2	Visual disturbance	16
5	53	M	NFA	-	TR	DM, BM	3	None	4
6	66	M	NFA	-	TR	DM, BM	4	None	4
7	71	F	NFA	+	PR	BM, CS	5	None	3
8	28	M	NFA	-	TR	DM	2	None	3
9	61	F	NFA	-	TR	DM, BM	3	None	2
10	12	M	Germinoma	-	Biopsy	BM, TB	3	None	2

BM: bony margin, CS: cavernous sinus, DM: dura mater of the sella floor, NFA: non-functioning adenoma, PR: partial removal, RCC: Rathke's cleft cyst, TB: tumor bed, TR: total removal.

sinus. Total volume of the injected MCH suspension ranged from 2 mL to 6 mL. The MCH suspension was easily and precisely applied at the bleeding points, and effective hemostasis was achieved in all cases. Furthermore, only small amount of the MCH remained on the point after irrigation, resulting that it did not prevent the further procedures. Applying the suspension on the dura mater of the sella floor or bony margins, hemostasis was typically achieved approximately in 2 min, while for hemostasis of the cavernous sinus it took between 3 min and 5 min after attempt of hemostasis using the standard techniques. The injection of MCH suspension was sometimes repeated twice on the same bleeding sites. No perioperative complication was encountered with the use of the MCH suspension. In Case 4, visual disturbance developed postoperatively probably due to chiasmal apoplexy, which might be caused by impaired blood flow of perforators after sudden collapse of the chiasm, without relation to this hemostatic technique.

Discussion

The procedure to achieve hemostasis in EETS is important, but it can be challenging because of a small access orifice diameter and a confined surgical space. In particular, bleeding from the cavernous sinuses sometimes cannot be easily halted; thus,

topical hemostatic agents play a crucial role in these situations. However, the insertion of topical hemostats using forceps can be hindered by the nasal mucosa and turbinates along the surgical route, which may result in hemostat contact with blood or body fluids. Furthermore, release of bloody or moist hemostats at the bleeding points can also be difficult because of its adhesion to tip the of forceps, and the swollen hemostats by moisture may make it difficult to perform the further procedures.

MCH is one of the most widely used topical hemostatic agents. It is made from purified bovine collagen and available as dry loose flour. When in contact with a bleeding surface, it promotes platelet aggregation, resulting in clot formation.¹⁾ Hemostatic benefits of MCH have previously been demonstrated in various laboratory and clinical studies. Moreover, MCH has been used in surgeries for decades to achieve hemostasis. However, this hemostat has a greater affinity for moist surfaces, such as gloves and any instruments, than do other agents.²⁾ Kassam et al. recently reappraised this product as an effective hemostat to achieve venous hemostasis in EETS using the "sandwich" method, in which MCH was sandwiched in a surgical patty, thus overcoming its adherence.³⁾

Currently, a gelatin-thrombin matrix hemostatic sealant (FloSeal®; Baxter Healthcare Corp, Fremont, California, USA or Surgiflo®; Ethicon Inc., Johnson &

Johnson Company, Somerville, New Jersey, USA) is commercially available and has been demonstrated to be effective in various surgical procedures, including EETS.⁴⁻⁶⁾ This material is a highly viscous gel that can be injected using a syringe with a special applicator. It can be accurately delivered to the bleeding points, and it remains where it is placed. The gelatin matrix, which is composed of cross-linked gelatin granules, swells by approximately 20% when in contact with blood, which, together with the action of thrombin, provokes hemostasis. At present, this hemostat appears to be best suited to achieve hemostasis in EETS;⁴⁻⁶⁾ however, in some countries, including Japan, this type of hemostat is not available, probably because of the cost or disallowance by governing regulatory authorities. This situation prompted us to determine compatible alternatives. MCH suspension had been reported to be safe and useful to achieve hemostasis after median sternotomy in cardiovascular surgery,⁷⁾ and at bone resection sites and extradural venous plexus in spine surgery.⁸⁾ We attempted to apply a similar method to achieve hemostasis in EETS and found that 1 g of MCH mixed with 9 mL of saline provides a suspension with a concentration that is well suited for injection using a syringe applicator; this suspension adapts to the configuration of the bleeding point and remains where it is placed. The method of injection of MCH suspension described here allowed a rapid and unimpeded delivery of the hemostat and may be more comfortable for surgeons during EETS compared with the typical use of the dry-flour form of MCH or other popular hemostats. In addition, we found that it is less expensive compared to the gelatin-thrombin matrix hemostatic sealant and that its hemostatic effect appears to be practically equivalent to that of dry MCH.

Use of MCH suspension to achieve hemostasis has the following debatable outcomes. First, several adverse events have been documented, including a theoretical risk of prion disease transmission, infections, systemic immunological responses, and granulomatous foreign body reaction.¹⁾ We should be aware of these risks, even though the incidence of clinically symptomatic events has been reported to be significantly low.^{9,10)} The direct application of MCH to neural tissue should be avoided. Second, MCH suspension may have a lesser hemostatic ability compared to the initial dry form, because it is recommended that it be used dry¹⁾; however, in practice, we observed satisfactory hemostasis during surgery using our method. We speculate that rapid and precise delivery of the hemostat, adaptation of the suspension to various configuration of the

bleeding point, and procedure used for the removal of moisture from the suspension at the bleeding point may have compensated for the reduction of the hemostatic effect.

Conclusion

With the advancement of EETS, not only for pituitary lesions but also for ventral skull-base lesions, more situations of bleeding have been frequently encountered. In this technical note, we described a method of injection of an MCH suspension and suggest that this technique may be useful to control the venous bleeding in EETS because of its simple, effective, and low-cost properties.

Acknowledgments

The authors thank Dr. Masahiro Nonaka, Dr. Yoshiko Okita, and Dr. Yuko Miyazaki, Department of Neurosurgery, National Hospital Organization Osaka Medical Center, Osaka, Japan, for their involvement of clinical and operative management of some of these patients.

Conflicts of Interest Disclosure

All of authors have nothing to be disclosed as Conflicts of Interest (COI). Yasunori Fujimoto, Akatsuki Wakayama, and Toshiki Yoshimine are members of the Japan Neurosurgical Society, and their COI status have been disclosed to the COI committee of the society. Taisuke Kobayashi, Masahiro Komori, Pedro Mariani, Edson Bor-Seng-Shu, and Manoel Jacobsen Teixeira are not members of the society, and they have nothing to be disclosed as COI.

References

- 1) Seyednejad H, Imani M, Jamieson T, Seifalian AM: Topical haemostatic agents. *Br J Surg* 95: 1197-1225, 2008
- 2) Rybock JD, Long DM: Use of microfibrillar collagen as a topical hemostatic agent in brain tissue. *J Neurosurg* 46: 501-505, 1977
- 3) Kassam A, Snyderman CH, Carrau RL, Garner P, Mintz A: Endoneurosurgical hemostasis techniques: lessons learned from 400 cases. *Neurosurg Focus* 19: E7, 2005
- 4) Ellegala DB, Maartens NF, Laws ER: Use of FloSeal hemostatic sealant in transsphenoidal pituitary surgery: technical note. *Neurosurgery* 51: 513-515; discussion 515-516, 2002
- 5) Cappabianca P, Esposito F, Esposito I, Cavallo LM, Leone CA: Use of a thrombin-gelatin haemostatic matrix in endoscopic endonasal extended approaches:

- technical note. *Acta Neurochir (Wien)* 151: 69–77; discussion 77, 2009
- 6) Fiss I, Danne M, Stendel R: Use of gelatin-thrombin matrix hemostatic sealant in cranial neurosurgery. *Neurol Med Chir (Tokyo)* 47: 462–467, 2007
 - 7) Hill RC, Kalantarian B, Jones DR: Use of microfibrillar collagen hemostat (Avitene) and thrombin to achieve hemostasis after median sternotomy. *J Thorac Cardiovasc Surg* 108: 1151–1152, 1994
 - 8) Tsuchiya K, Yamaoka K, Miyagi M, Okamura T: [Consideration of topical hemostats in spinal surgery: a novel usage of microfibrillar collagen]. *Orthopedics & Traumatology* 56: 664–668, 2007 (Japanese)
 - 9) O'Shaughnessy BA, Schafernak KT, DiPatri AJ Jr, Goldman S, Tomita T: A granulomatous reaction to Avitene mimicking recurrence of a medulloblastoma. Case report. *J Neurosurg* 104(1 Suppl): S33–S36, 2006
 - 10) Bloomfield MR, Klika AK, Molloy RM, Froimson MI, Krebs VE, Barsoum WK: Prospective randomized evaluation of a collagen/thrombin and autologous platelet hemostatic agent during total knee arthroplasty. *J Arthroplasty* 27: 695–702, 2012
-
- Address reprint requests to:* Yasunori Fujimoto, MD, PhD, Department of Neurosurgery, Osaka Neurological Institute, 2-6-23 Shonai Takara-machi, Toyonaka, Osaka 561-0836, Japan.
e-mail: yasufujimoto@gmail.com