

A Modified Combined Transseptal/Transnasal Binostril Approach for Pituitary Lesions in Patients with a Narrow Nasal Space: Technical Note

Mitsuhiro TAKEMURA,¹ Yasunori FUJIMOTO,¹ Taisuke KOBAYASHI,²
Masahiro KOMORI,² Aldo C STAMM,³ Eduardo VELLUTINI,⁴ Pedro MARIANI,⁵
Yu KAWANISHI,¹ and Keiji SHIMIZU¹

Departments of ¹Neurosurgery and ²Otorhinolaryngology, Kochi Medical School, Kochi University, Nankoku, Kochi;

³São Paulo ENT Center, Complexo Hospitalar Edmundo Vasconcelos, São Paulo, Brazil;

⁴Department of Neurosurgery, DFV NEURO, São Paulo, Brazil;

⁵Department of Neurosurgery, Hospital Euryclides de Jesus Zerbini, São Paulo, Brazil

Abstract

We describe a modification of the combined transseptal/transnasal binostril approach using a two-surgeon, four-handed technique (modified Stamm's approach) for pituitary lesions in patients with narrow nasal spaces. This approach comprises of a transseptal route through one nostril and a transnasal route without harvesting a pedicled nasoseptal flap (NSF) through the other. On the transseptal side, the nasal septum was removed using an endoscopic septoplasty technique. On the transnasal side, the mucosa containing the septal branch of the sphenopalatine artery over the face of the sphenoid and nasal septum was preserved for harvesting the NSF if an intraoperative cerebrospinal fluid leak was encountered. This approach was performed in six patients with pituitary lesions, including four non-functioning macroadenomas, one growth hormone-producing macroadenoma, and one Rathke's cleft cyst, all of which were associated with a severe deviation of the nasal septum and/or narrow nasal space. The meticulous and comfortable manipulation of an endoscope and instruments were achieved in all six patients without surgical complications. Our findings, although obtained in a limited number of cases, suggest that the modified Stamm's approach may be useful for selected patients, particularly those with a severe deviation of the nasal septum, without considerable damage to the nasal passages.

Key words: endoscopic endonasal surgery, pituitary lesions, narrow nasal space, modified Stamm's approach, two-surgeon four-handed technique

Introduction

The endoscopic combined transseptal/transnasal binostril approach, which was introduced first by Stamm et al. (Stamm's approach), has usually been applied for transnasal endoscopic skull base and brain surgery.¹⁾ This approach is useful for ventral skull base lesions because it can provide a larger surgical corridor for the two-surgeon, four-handed technique compared to the corridor available in a standard transnasal approach. Meanwhile, various sinonasal procedures and their combinations are frequently required to enlarge the surgical corridor in patients with narrow nasal spaces caused by

anatomic variations, including deviation of the nasal septum, septal spur, concha bullosa, and conchal hypertrophy.^{2,3)} In patients with pituitary lesions associated with a narrow nasal space, we have applied the modified Stamm's approach or a combined transseptal/transnasal binostril approach without harvesting a pedicled nasoseptal flap (NSF) on the transnasal side. Here, we report the usefulness of this approach when used in combination with the two-surgeon, four-handed technique.

Materials and Methods

We performed the modified Stamm's approach in six patients with pituitary lesions. Preoperative evaluations by ear, nose, and throat (ENT) surgeons

had revealed that the nasal space on at least one side was too narrow for meticulous and comfortable use of an endoscope and instruments. The original technique was previously described by Stamm et al.¹⁾ As part of our preparation for the procedure, the nasal mucosa in the surgical corridor was decongested with cottonoids containing epinephrine in a 1:5,000 dilution. The septum was infiltrated with 1% lidocaine and epinephrine in a 1:100,000 dilution. The middle and superior turbinates were compressed and outfractured laterally at the base. A nasal septal hemitransfixion incision was placed unilaterally and subperichondrial/periosteal dissection was performed, reaching the anterior wall of the sphenoid sinus (Fig. 1A). A vertical incision was placed in the cartilage 1 cm posterior from the anterior limit, and subperichondrial/periosteal dissection was also performed on the contralateral side. The cartilage was cut off 1 cm from the anterior and 1 cm from the superior limit of the septum, preserving the “L”-shaped strut of the cartilage. The bony septum was also removed, leaving the inferior portion as a midline landmark. This “L”-shaped cut of the septum using the endoscopic septoplasty technique allowed us to avoid a saddle-nose deformity. The septal flap, elevated from the septum, was set apart from the midline as far as possible (Figs. 1B, 2B) and was temporarily sutured to the nasal ala so that we could smoothly maneuver an endoscope and instruments in and out. The sphenoid ostia was enlarged and a wide sphenoidotomy was performed through this transseptal route (Figs. 1B, 3D). Through the contralateral nostril, the mucosa of the face of

the sphenoid and posterior septum were resected, providing a transnasal route (Figs. 1B, 3C). On this side, care should be taken to preserve the mucosa containing the septal branch of the sphenopalatine artery and to minimize the resection of the posterior septal mucosa for harvesting the NSF, when necessary.⁴⁾ In some cases, the horizontal incision was placed at the level of the ostium and continued anteromedially into the posterior nasal septum, which would enable the rescue flap technique (Fig. 2B).⁴⁾ The combination of both routes allowed a neurosurgeon and an ENT surgeon to employ a binostril approach using a two-surgeon, four-handed technique (Figs. 1, 2). At the end of surgery, the septal flap was coapted using an absorbable suture. The nasal packing was left in place to prevent a hematoma and promote the healing of mucosal scarring.

Results

Table 1 provides a summary of the patients' characteristics. There were four males and two females aged 27–60 years (mean, 39 years). Four patients had nonfunctioning pituitary macroadenomas and one had a growth hormone-producing macroadenoma with clinical characteristics of acromegaly. All these patients underwent total tumor resection. Another patient who had a Rathke's cleft cyst underwent drainage and biopsy of the cyst. During surgery, the ENT surgeons smoothly maneuvered the endoscope in and out while the neurosurgeons manipulated instruments meticulously, with minimum interference by the nasal

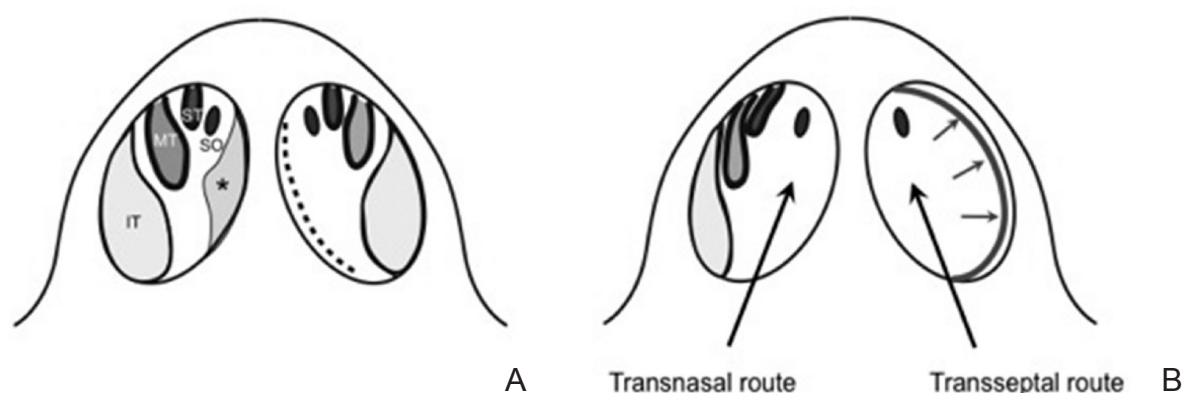


Fig. 1 Schematic drawing showing the anatomical landmarks in the nasal cavities before (A) and after (B) the modified Stamm's approach. The dotted line shows the hemitransfixion incision on the left nasal septum (A). On the right side, the middle and superior turbinates are compressed and outfractured laterally at the base, providing a transnasal route. The sphenoid ostium covered by the mucosa is visible. On the left side, the septal flap made by subperichondrial/periosteal dissection is set apart laterally from the midline as far as possible, providing a transseptal route (B). The bony sphenoid ostium is exposed by peeling off the mucosa over the rostrum of the sphenoid sinus. Asterisk: septal spur with a deviated nasal septum, IT: inferior turbinate, MT: middle turbinate, small *arrows*: the septal mucosa dissected from the nasal septum, SO: sphenoid ostium, ST: superior turbinate.

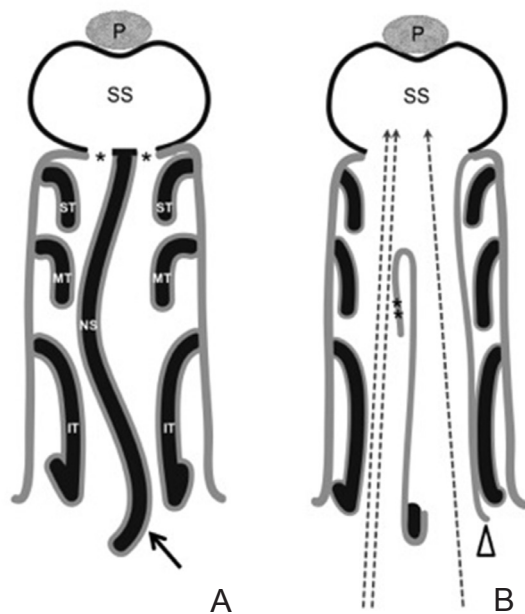


Fig. 2 Schematic drawing showing the axial sections of the surgical field along with the trajectory of an endoscope in a patient with a small nasal cavity due to a deviated septum before (A) and after (B) this approach. Septoplasty provides both wider transnasal and transseptal routes, and any instrument can be manipulated without interference of the nasal turbinates through the transseptal route (B). *Arrow*: hemitransfixion incision on the left septal mucosa, *arrowhead*: the nasal mucosa dissected from the nasal septum on the left side, *asterisk*: sphenoid ostium, *dotted arrow*: the trajectory of an instrument through the transseptal route, *double asterisks*: rescue flap, *double dotted arrow*: the trajectories of an endoscope and a suction tube through the transnasal route, IT: inferior turbinate, MT: middle turbinate, P: pituitary gland, SS: sphenoid sinus, ST: superior turbinate.

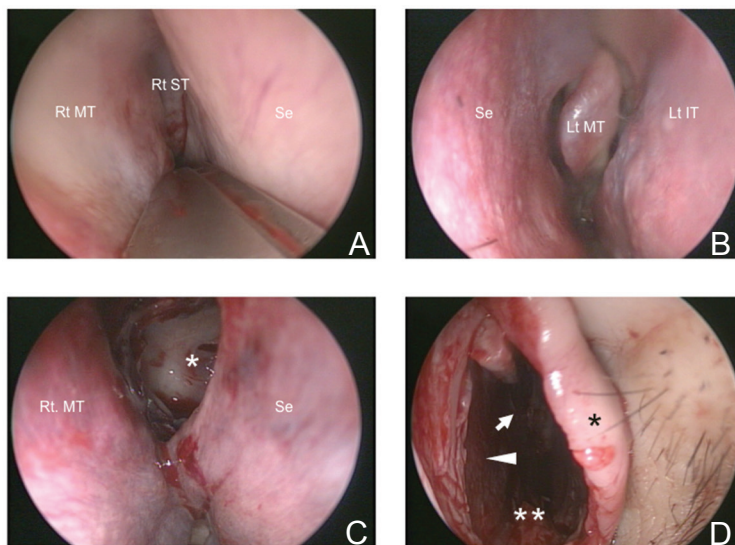


Fig. 3 Case 1. Endoscopic view from the right (A, C) and left (B, D) nostril during surgery. The right nasal space is so narrow that bimanual manipulation of instruments by a two-surgeon, four-handed technique would be limited because of deviation of the nasal septum (A). After employing the modified Stamm's approach, the sphenoid ostium was enlarged and the sella floor was observed through the transnasal route on the right side (C). On the left side, the cartilaginous and bony septa were removed and the septal flap was set apart laterally, which provided a transseptal route (D). *Arrow*: sphenoid sinus, *arrowhead*: medial aspect of the right septal mucosa, *asterisk*: sella floor, *black asterisk*: anterior edge of the septal flap dissected from the nasal septum, *double asterisks*: maxillary crest, MT: middle turbinate, Se: nasal septum.

mucosa and turbinates. Additional procedures were necessary in three of the six patients, including partial removal of the lateral aspect of the middle turbinate because of the concha bullosa in two patients and submucosal turbinectomy because of the hypertrophied inferior turbinate in one patient, respectively. There were no postoperative surgical complications.

Illustrative Cases

I. Case 1

A 29-year-old woman presented with amenorrhea. Magnetic resonance imaging (MRI) revealed

a pituitary macroadenoma, which proved to be nonfunctioning as per endocrinological examinations (Fig. 4A, B). Computed tomography (CT) revealed a deviation of the nasal septum to the right side as well as a concha bullosa of the left middle turbinate (Fig. 4C, D). During surgery, a significantly narrow nasal space was confirmed on the right side (Fig. 3A, B). These observations prompted us to apply the modified Stamm's approach, which combined a transseptal approach on the left side with a transnasal approach on the right side (Fig. 3C, D). Total tumor resection was achieved and the patient was discharged 12 days after surgery without any complications. Outpatient

Table 1 Summary of cases

Case no.	Age (years)	Sex	Pathology	Knosp's classification (Grade)	Associated anatomical variations and pathologies	Additional procedures	Complications
1	29	F	NFA	2	NSD, concha bullosa, septal spur	Removal of the lateral part of the MT	No
2	60	M	Rathke's cleft cyst	NA	NSD, maxillary sinusitis, hypertrophic inferior turbinate	Submucosal inferior turbinectomy	No
3	31	M	GHoma	2	Septal spur, hypertrophic nasal turbinates	No	No
4	38	M	NFA	3	NSD, maxillary sinusitis	No	No
5	47	F	NFA	2	NSD	No	No
6	27	M	NFA	3	NSD, septal spur, concha bullosa	Removal of the lateral part of the MT	No

GHoma: growth hormone-producing macroadenoma, MT: middle turbinate, NA: not applicable NFA: nonfunctioning macroadenoma, NSD: nasal septal deviation.

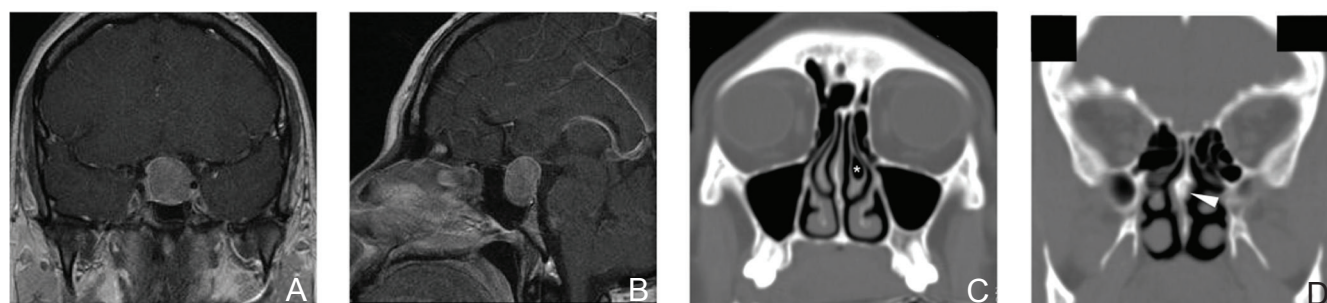


Fig. 4 Case 1. Preoperative coronal (A) and sagittal (B) magnetic resonance images after administration of contrast medium show a homogeneously enhanced macroadenoma. Preoperative coronal computed tomography scans (C, D) show the concha bullosa of the left middle turbinate (*asterisk*) and deviation of the nasal septum to the right side (*arrowhead*).

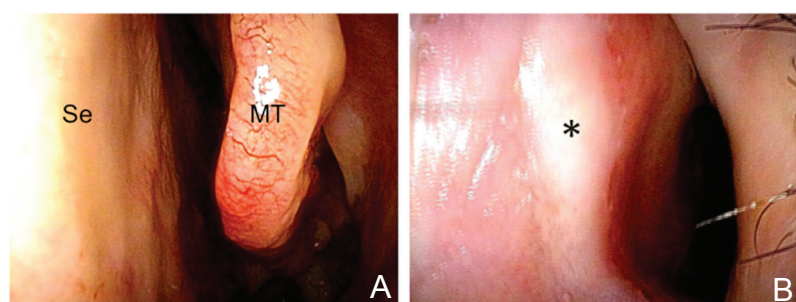


Fig. 5 Case 1. Postoperative endoscopic view at outpatient evaluation 25 days after surgery shows good healing of the mucosa of the left middle turbinate (A) and the nasal septal hemitransfixion incision without a septal perforation in the left nostril (B). *Asterisk*: scar of hemitransfixion incision, MT: middle turbinate, Se: nasal septum.

evaluation performed 25 days after surgery showed good healing of the nasal mucosa and no septal perforation (Fig. 5A, B).

II. Case 2

A 60-year-old man presented with a dull headache and homonymous hemianopsia. MRI revealed a large cystic mass in the sellar and suprasellar regions,

suggestive of a Rathke's cleft cyst (Fig. 6A, B). CT revealed a remarkable deviation of the nasal septum to the left side, associated with hypertrophy of the right inferior turbinate and chronic sinusitis in the right maxillary sinus (Fig. 7A, B). Outpatient endoscopic observation of the nasal cavity confirmed a significantly narrow nasal space on both sides (Fig. 7D, E).

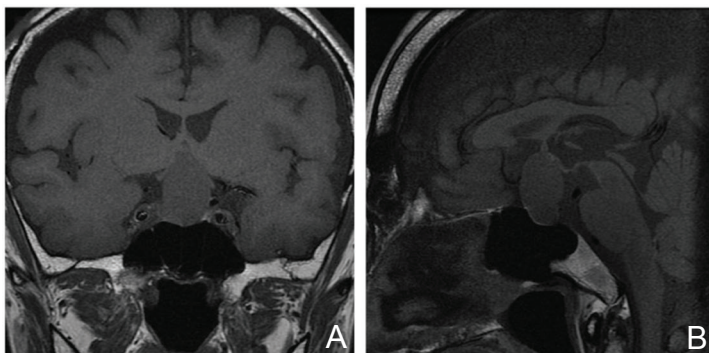


Fig. 6 Case 2. Preoperative coronal (A) and sagittal (B) T₁-weighted magnetic resonance images show a homogenous cystic mass compressing the chiasm, suggestive of a Rathke's cleft cyst.

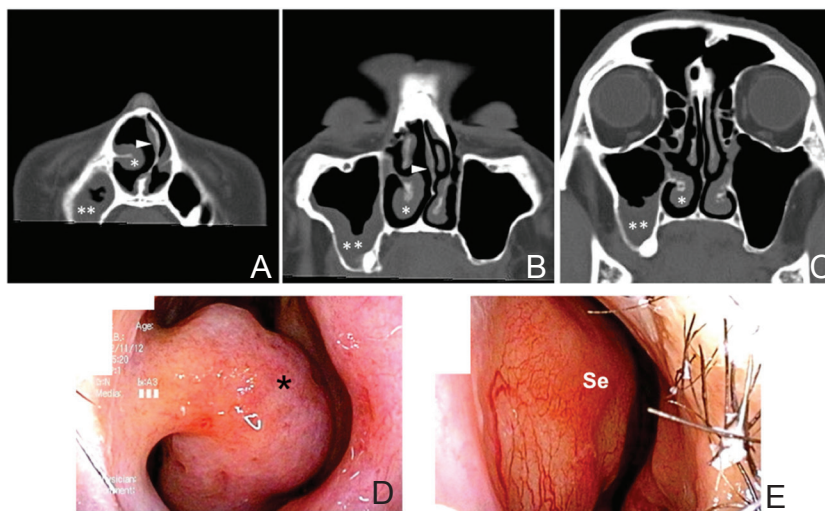


Fig. 7 Case 2. Preoperative computed tomography (CT) scans (A–C) and outpatient endoscopic views of the right (D) and left (E) nasal cavity. CT scans reveal deviation of the nasal septum to the left and hypertrophy of the right inferior turbinate and chronic maxillary sinusitis on the right. Preoperative outpatient endoscopic evaluation confirmed narrow nasal spaces on both sides because of the hypertrophied right inferior turbinate (D) and protrusion of the nasal septum in the left nasal cavity (E). *Arrowhead*: deviated nasal septum, *asterisk*: hypertrophied right inferior turbinate, *double asterisks*: chronic sinusitis in the right maxillary sinus, *Se*: nasal septum.

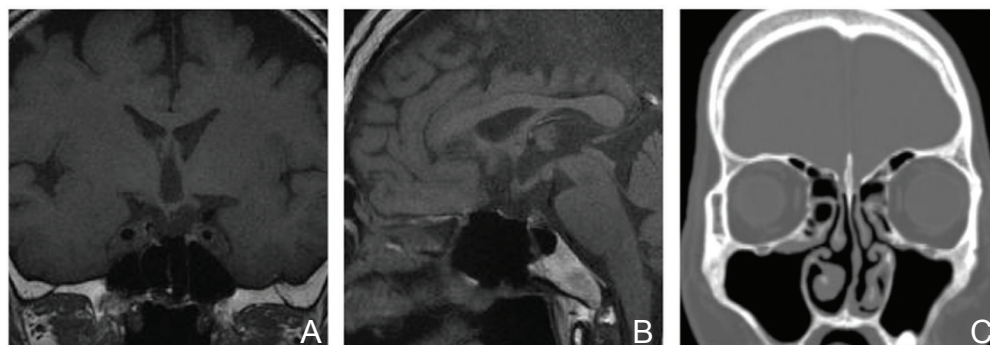


Fig. 8 Case 2. Postoperative coronal (A) and sagittal (B) T₁-weighted magnetic resonance images and coronal computed tomography scans (C). The cyst has disappeared and good decompression of the optic chiasm is achieved (A, B). The chronic sinusitis in the right maxillary sinus has also improved (C).

On the basis of these preoperative findings, which predicted difficulty in smooth maneuvering of an endoscope and instruments, we decided to employ the modified Stamm's approach. The offending septal cartilage and bone were removed through the transseptal incision in the left nostril. Right submucosal inferior turbinectomy was also performed, but the right maxillary sinus was not opened. This approach provided an enlarged surgical corridor for smooth and comfortable manipulation

of the endoscope and instruments. Drainage and biopsy of the cyst was successfully achieved and the patient's clinical symptoms were alleviated. The patient was discharged 14 days after surgery without any surgical complications. Pathological examination confirmed the diagnosis of Rathke's cleft cyst. Postoperative MRI revealed good decompression of the optic chiasm (Fig. 8A, B), while CT revealed alleviation of the chronic sinusitis in the right maxillary sinus (Fig. 8C).

Discussion

There are several procedures to enlarge a surgical space in the nasal cavity for endoscopic endonasal surgery (EES), including superior, middle, and inferior turbinectomies, anterior and/or posterior ethmoidectomy, and their combinations. Septoplasty or removal of deviated bony and cartilaginous septa, is commonly performed for the treatment of nasal airway obstruction and the improvement of surgical access for EES.⁵⁾ Septoplasty can also refer to clearing away of obstacles to reach the anterior wall of the sphenoid sinus through the sphenoidal recess during endoscopic endonasal transsphenoidal surgery.^{6,7)} When a small septal spur protrudes, local submucosal dissection of only the spur would resolve the problem.⁸⁾ However, a prominent deviation of the nasal septum would require removal of the deviated septum in some cases.

The endoscopic combined transseptal/transnasal binostril approach using a two-surgeon, four-handed technique (Stamm's approach) can provide a single, wide surgical corridor. This is achieved through a combination of septoplasty and NSF harvest, which has been proved to be a robust and reliable method for preventing postoperative cerebrospinal fluid (CSF) leakage.^{1,9)} However, standard pituitary surgery does not usually require either the NSF or the two-surgeon, four-handed technique. Meanwhile, the two-surgeon, four-handed technique not only provides dynamic movement of an endoscope by an ENT surgeon, offering a clean and pseudo-three dimensional visual field, but also allows for smooth and comfortable manipulation of instruments.^{10,11)} In addition, the partnership between an ENT surgeon and a neurosurgeon greatly enhances knowledge

about the nasosinusal and intracranial anatomies, various pathologies in these areas, control of intra- and postoperative bleeding, and skull base reconstruction.^{9,12)} Therefore, as a premise for using the two-surgeon, four-handed technique, we modified the Stamm's approach for patients with common pituitary lesions, particularly those associated with a narrow nasal space.

The technique described here, which we call the modified Stamm's approach, has the following advantages. First, it is suitable for pituitary lesions associated with narrow nasal spaces because it allows for a wide surgical corridor to the sella without causing considerable damage to the nasal mucosa. Second, the maneuvering of instruments in and out through the transseptal route cannot be prevented by the nasal turbinates and/or septal mucosa, which would frequently interrupt the smooth insertion of instruments via a direct transnasal route. Third, if an intraoperative CSF leak is encountered, the NSF can be harvested or the previously prepared rescue flap can be converted into the NSF for sellar reconstruction. Finally, it can collaterally improve patients' symptoms due to chronic nasosinusal diseases such as chronic sinusitis associated with septal deviation and other nasal anatomical variations by relieving the obstruction and stagnation of secretions or improving nasal aerodynamics.^{2,3,13,14)} However, this approach also has potential disadvantages. Dissection of the septal mucosa is somewhat time-consuming; it can lead to a septal perforation and may, in rare cases, cause transient dental pain or hyperesthesia.¹⁵⁾ Nasal packing is necessary to prevent hematoma formation and promote mucosal healing, leading to patient suffering. Table 2 summarizes the concepts and characteristics of three different

Table 2 Summary of the concepts and characteristics of three different approaches for the pituitary lesions

Approach	Surgeon	Endoscope	Instruments	Nasal septum and septal mucosa	Septal perforation	Invasiveness to nasosinusal structures	Size of surgical corridor
Common binostril approach	Single surgeon	Fixed, through transnasal route	Through transnasal routes	Posterior septectomy	Yes	Regular	Regular
Stamm's approach	Two-surgeon four-handed	Freehand, through transseptal route	Through transseptal and transnasal routes	Nasal septal flap is harvested through transnasal route and posterior part of the nasal septum is removed. The septal mucosa is preserved on the other side	No	High	Large
Modified Stamm's approach	Two-surgeon four-handed	Freehand, through transnasal route	Through transseptal and transnasal routes	Bony and cartilaginous septa are removed as a septoplasty. Rescue flap can be made through transnasal route and septal mucosa is preserved on the other side	No	Medium	Medium

binostril approaches for the pituitary lesions: common binostril approach, original Stamm's approach, and modified Stamm's approach.

Conclusion

Although the original Stamm's approach is useful for ventral skull base lesions, it may be invasive for simple pituitary lesions. We assume that our modified Stamm's approach combined with the two-surgeon, four-handed technique for pituitary lesions is less invasive compared to the original technique and is suitable for selected patients, particularly those with a narrow nasal space.

Conflicts of Interest Disclosure

The authors have nothing to be disclosed as Conflicts of Interest (COI). Mitsuhiro Takemura, Yasunori Fujimoto, Yu Kawanishi, and Keiji Shimizu are members of the Japan Neurosurgical Society, and their COI status have been disclosed to the COI committee of the society. Taisuke Kobayashi, Masahiro Komori, Aldo C. Stamm, Eduardo Vellutini, and Pedro Mariani are not members of the society, and they have nothing to be disclosed as COI.

References

- 1) Stamm AC, Pignatari S, Vellutini E, Harvey RJ, Nogueira JF: A novel approach allowing binostril work to the sphenoid sinus. *Otolaryngol Head Neck Surg* 138: 531–532, 2008
- 2) Stammberger H, Posawetz W: Functional endoscopic sinus surgery. Concept, indications and results of the Messerklinger technique. *Eur Arch Otorhinolaryngol* 247: 63–76, 1990
- 3) Yasan H, Dođru H, Baykal B, Döner F, Tüz M: What is the relationship between chronic sinus disease and isolated nasal septal deviation? *Otolaryngol Head Neck Surg* 133: 190–193, 2005
- 4) Rivera-Serrano CM, Snyderman CH, Gardner P, Prevedello D, Wheless S, Kassam AB, Carrau RL, Germanwala A, Zanation A: Nasoseptal "rescue" flap: a novel modification of the nasoseptal flap technique for pituitary surgery. *Laryngoscope* 121: 990–993, 2011
- 5) Sautter NB, Smith TL: Endoscopic septoplasty. *Otolaryngol Clin N Am* 42: 253–260, 2009
- 6) van Lindert EJ, Ingels K, Mylanus E, Grotenhuis JA: Variations of endonasal anatomy: relevance for the endoscopic endonasal transsphenoidal approach. *Acta Neurochir (Wien)* 152: 1015–1020, 2010
- 7) Zada G, Cavallo LM, Esposito F, Fernandez-Jimenez JC, Tasiou A, De Angelis M, Cafiero T, Cappabianca P, Laws ER: Transsphenoidal surgery in patients with acromegaly: operative strategies for overcoming technically challenging anatomical variations. *Neurosurg Focus* 29: E8, 2010
- 8) Castelnuovo P, Pagella F, Cerniglia M, Emanuelli E: Endoscopic limited septoplasty in combination with sinonasal surgery. *Facial Plast Surg* 15: 303–307, 1999
- 9) Hadad G, Bassagasteguy L, Carrau RL, Mataza JC, Kassam A, Snyderman CH, Mintz A: A novel reconstructive technique after endoscopic expanded endonasal approaches: vascular pedicle nasoseptal flap. *Laryngoscope* 116: 1882–1886, 2006
- 10) Robinson S, Patel N, Wormald PJ: Endoscopic management of benign tumors extending into the infratemporal fossa: a two-surgeon transnasal approach. *Laryngoscope* 115: 1818–1822, 2005
- 11) Stamm AC, Vellutini E, Harvey RJ, Nogueira JF, Herman DR: Endoscopic transnasal craniotomy and the resection of craniopharyngioma. *Laryngoscope* 118: 1142–1148, 2008
- 12) Kassam A, Snyderman CH, Carrau RL, Gardner P, Mintz A: Endoneurosurgical hemostasis techniques: lessons learned from 400 cases. *Neurosurg Focus* 19: E7, 2005
- 13) Blaugrund SM: Nasal obstruction. The nasal septum and concha bullosa. *Otolaryngol Clin North Am* 22: 291–306, 1989
- 14) Collet S, Bertrand B, Cornu S, Eloy P, Rombaux P: Is septal deviation a risk factor for chronic sinusitis? Review of literature. *Acta Otorhinolaryngol Belg* 55: 299–304, 2001
- 15) Chung BJ, Batra PS, Citardi MJ, Lanza DC: Endoscopic septoplasty: revisitation of the technique, indications, and outcomes. *Am J Rhinol* 21: 307–311, 2007

Address reprint requests to: Yasunori Fujimoto, MD, PhD, Department of Neurosurgery, Kochi Medical School, Kochi University, Oko-cho Kohasu, Nankoku, Kochi 783-8505, Japan.
e-mail: yasufujimoto@gmail.com